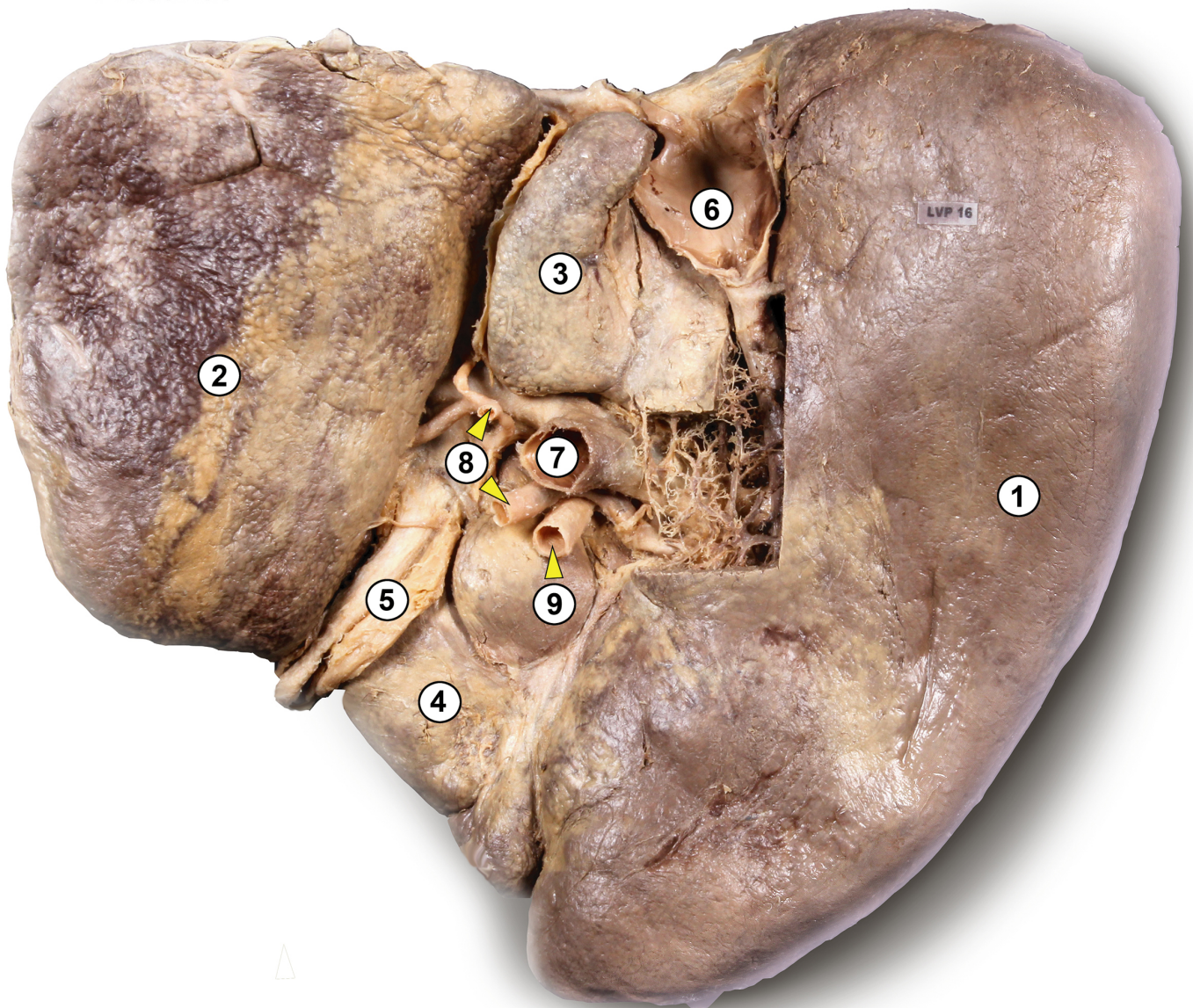


# Leber

Plastinat



- 1 rechter Leberlappen *Lobus hepatis dexter*
- 2 linker Leberlappen *Lobus hepatis sinister*
- 3 „geschwänzter“ Lappen *Lobus caudatus*
- 4 quadratischer Lappen *Lobus quadratus*
- 5 rundes Ligament der Leber *Ligamentum teres hepatis*
- 6 untere Hohlvene *Vena cava inferior*
- 7 Pfortader *Vena portae hepatis*
- 8 Äste der *Arteria hepatica propria*
- 9 Gallengang *Ductus choledochus*